



Journal of Home Economics

Volume 24, Number (3), 2014

<http://homeEcon.menofia.edu.eg>

**Journal of Home
Economics**

ISSN 1110-2578

Dietary Fiber Rich Biscuits As Effecting On Obese And Diabetic Rats

Hanan S. Shalaby¹ and Gehan A. El-Shourbagy²

Food Science Department, (Rural Home Economics), Faculty of Agric., Zagazig Univ., Egypt.¹, Food Science Department, Faculty of Agric., Zagazig Univ., Egypt.²

Abstract: The dietary fiber rich biscuits had the nutritional therapeutic properties for obesity and diabetic patients. Fiber-enriched biscuits were prepared from selected oat and peanut skin. Consumption of this natural bioactive ingredient as offers health benefits including protection against cardiovascular diseases. In the present study, oat and peanut skin were incorporated into biscuits and fed vs. commercial biscuit to groups being obese and diabetic rats. Rats monitored daily for feed intake, blood glucose and bodyweight gain were received dietary fiber biscuits and commercial biscuit. They rats were sacrificed by cervical dislocation after a 12-week treatment. Blood serum and liver, heart and pancreas investigated histopathologically. Total cholesterol, triglyceride, HDL, and LDL, after 3 months were analyzed.

The final results showed that oat and peanut skin biscuits could acted a little on the organoleptic properties and had reduced the body weight of rats an adjuvant therapy for metabolic disorders. As shown from results serum parameters for peanut skin and oat biscuits lowered total cholesterol, LDL, triglyceride while increasing HDL with improved properties and histological sectors of liver, heart and pancreas. Consumption as daily supplement, oat and peanut skin could act as an adjuvant therapy for obesity and diabetes.

Keywords : Dietary fiber biscuits, Obesity , Diabetes, Biscuits.

Introduction

Diederick, (2015) described the various compounds that can act as prebiotic fibers:, their structure, occurrence, production, and physiological effects (health effects) were presented. Wheat grain and its technological fractions bran and aleurone are rich in nutritional compounds such as dietary fiber and photochemical, which are recognized as having high health benefits. These bioactive compounds are embedded in the complex cellular and molecular structures of the

wheat matrix. The matrix structure influences their bioaccessibility and bioavailability, probably altering their metabolic and health effects ([Natalia et al., 2015](#)).

Biscuits are the most popularly consumed bakery item in Egypt and other parts of the world. Some of the reasons for such wide popularity are their ready to eat nature, affordable cost, good nutritional quality, availability in different tastes and longer shelf life (**Gandhi et al., 2001**). Because of competition in the market and increased demand for healthy, natural and functional products, attempts are being made to improve biscuits' nutritive value and functionality by modifying their nutritive composition. Such effects are very often achieved by increasing the ratios of whole grain raw materials other than wheat flour or different types of dietary fiber in basic recipes with the attempt to increase biscuit's protein content and quality, mineral content and availability (**Hooda and Jood, 2005, Tyagi et al., 2007 and Vitali et al., 2009**) or increase dietary fiber content and improved prebiotical characteristics of the final product (**Gallagher et al., 2003 and Vitali et al., 2009**).

The importance of food, rich in dietary fiber and antioxidants, increased in recent decades food constituents has led to the development of racial markets for fiber and antioxidant rich products and ingredients. Intake of dietary fiber and phytochemicals such as polyphenols, carotenoids, tocopherols and ascorbic acid have been related to the maintenance of health and protection from diseases such as cancer, cardiovascular diseases and many other degenerative diseases (**Block and Langseth, 1994; Wang and Jiao, 2000 and Ajila et al., 2008**). The high concentration of polyphenols present in peels, skins and seeds support the utilization of agricultural by products as source of natural antioxidants seeds. (**Maria, 2009a,b**). The whole-grain oat cereal reduced LDL-C more than the low-fiber foods for adults with overweight and obesity (**Maki et al., 2010**).

Peanut skins have a pink-red color and an astringent mouth feel when consumed. They are typically removed before peanut consumption or inclusion in confectionary and snack products (**Maria 2009a,b**). Peanut skins contain potent antioxidants and could provide an inexpensive source of polyphenols for use as functional ingredients in foods or dietary supplements (**Maria 2009a,b**). However oat fiber is a rich source of β -glucans, known for their ability to lower serum cholesterol levels in men (**Anderson et al., 1990; Davy et al., 2002 and Queenan et al., 2007**). Oat-derived beta-glucan increased HDLC, while diminished LDLC and non-HDL cholesterol levels in overweight individuals with hypercholesterolemia (**Davy et al., 2002; Queenan et al., 2007 and Reyna-Villasmil et al., 2007**).

Obesity and body fat deposition play a critical role in the pathogenesis of metabolic disorders, including metabolic syndrome and cardiovascular disease (**Calle et al., 1999**). There is a metabolic link between the expanded body fat, high triglycerol (TG), high low density lipoprotein cholesterol (LDL-C), low high-density lipoprotein cholesterol (HDL-C) and insulin resistance, which leads to impaired metabolic regulation in adipose tissue and flux of free fatty acids (FFA) (**Despres, 2006**).

Nutrition has been described as an integral component in the overall concept of well being, with proper nutrition playing a major role in the prevention and treatment various diseases and ailments (**Polikandrioti and Dokoutsidou, 2009**). A healthy nutrition well combined with exercise and proper medication has been widely accepted as the basis for a long and productive life for diabetics (**Polikandrioti and Dokoutsidou, 2009**). Healthy nutrition has been shown to contribute positively to the maintenance of normal blood glucose level and prevention of several diabetic complications which include cardiovascular disease (CVD), retinopathy, nephropathy, neuropathy, and micro vascular damage to the cerebral artery (**Maritimi et al., 2003**).

Overweight, obesity, and diabetes are the most common disorders in the world. In most diets, carbohydrates are the greatest source of calories. Inhibition of carbohydrate digestion or absorption can decrease calorie intake to promote weight loss and combat obesity. It is also a mechanism for reducing hyperglycemia in diabetic subjects (**Najafian, 2014**).

Diabetes mellitus affects people of all ages and ethnic groups. It was estimated that 2.8% of the world's population was diabetic in 2000 and this figure would climb to be as high as 4.4% of the world's population by 2030 (**Wild et al., 2004**). Diabetes is a deadly disease that affected an estimated 285 million people worldwide in 2010, the number is increasing in rural and poor populations throughout the world, and is projected to become one of the world's main disablers and killers within the next 25 years (**Shaw et al., 2010**). The developed countries such as India, China, and the U.S. are presently the countries with the leading number of diabetics. Furthermore, seven percent of the residents of the United States are diabetic. Though it is a non-communicable disease, but is considered to be one of the five leading causes of death worldwide (**Chakraborty and Das, 2010**). The present study was carried out to produce biscuits rich in dietary fiber for those suffering obesity and diabetes.

2. Materials and methods

2.1. Materials

Wheat flour 72 %, oat flour , bran powder , sugar ,baking powder , cinnamon, fat ,maize oil, vanillin, and eggs, were obtained from local market ,Zagazig ,Egypt . Kits (cholesterol , HDL cholesterol , triglycerides)and Streptozotocin were purchased from Sigma-Chemical Company, Egypt).

2.2. Preparation of biscuits.

2.2.1. Commercial biscuit.

Biscuit was prepared as the following method by (**Tiwari et al., 2011**) using fat (132.5 g), sugar (265 g) and eggs (4 units) which were mixed for 3-4 min in a Hobart mixer. Wheat flour (500 g)), packing powder (0.5 g),vanillin (0.1g) and water were mixed together in a bowl to the dough. The specified amount of water was added gradually during continuous mixing until a slightly firm dough was obtained. The dough was spread on a clean flat surface and cut into fine circles and stars of biscuit. Biscuits were transferred onto metal trays and allowed to bake in an oven for 30 min at a temperature of 150 C. After preparation the biscuits were allowed to cool, wrapped with aluminum foil and stored at 4C.

2.2.2.Preparation of rich dietary fiber biscuits .

Rich dietary fiber biscuits were prepared according to method described by **Ochuko et al., (2013)** with some modification as follows: 250 g wheat flour (72%) 500g dietary fiber (250g bran powder +250g oat or peanut skin or peanut skin and oat 1:1) were used. Biscuits dry ingredients were mixed with a mixer to form dough. The processing of these types of fiber biscuits was carried as shown in the previous commercial biscuit.

2.3. Chemical analysis

Moisture, crude protein, crude fat ,crude fiber and ash content were determined according to the methods outlined in **AOAC (2001)** in raw materials and biscuits. Total carbohydrates was calculated by differences .

2.4. Sensory evaluation of biscuits.

Sensory characteristics of biscuits were conducted according to (**Hooda and Jood, 2005**). Samples were presented in a sealed pouch coded with different numbers to six panelists who were asked to rate their sensory attributes. Biscuits were evaluated for surface color, texture, taste, flavor, mouth feeling and overall quality on a 9-point hedonic scale.

2.5. Animals experiments.

Albino rats, Sprague –Dawleys strain were used. Animals were kept in animal house at an ambient temperature of 25–30 C and 45–55%

relative humidity with a 12h each of dark and light cycle. Animals were fed pellet diet and water ad libitum. The experimental protocol has been approved by Faculty of Veterinary Medicine, Zigzag University, Dept. Histology and Cytology. Treatment lasted for 4 weeks to carry out the biological evaluation of serum using Kits (CH. Millour, Italy and biological). At the end of the feeding trials, the rats were fasted overnight and sacrificed by cervical dislocation.

Obesity rats: Adult 24 albino male average weight 220 -250 g rats (obesity) were divided into four groups, each consisting of six animals (n=6rats).

Diabetes rats : Induction of diabetes carried out using 24 male albino rats, average weight 120 +_5 g which were divided into four groups and subjected to Streptozotocin (STZ) injection at a dose of 50 mg/kg in 0.1 M citrate buffer (pH 4.5) (Hemalatha *et al.*, 2004). The animals were allowed to drink 5% glucose solution to overcome the drug (Balasubramaian *et al.*, 2004). Fasting blood glucose levels were measured after 5 days, animal with blood glucose concentration level above 250 mg/dL were separated and used for the study. The rats were monitored daily for food and body weight. Blood glucose levels of the rats were monitored on weekly basis with a Glucometer elite commercial test (Bayer), based on the glucose oxidize method. Blood samples were collected from the tip of tail at the defined time patterns (Aslan *et al.*, 2007a,b).

2.6. Blood sampling and biochemical analysis.

Blood was collected with a 5 ml syringe and needle by cardiac puncture. It was centrifuged at 3000 rpm for 10 min and the serum (supernatant) was analyzed for determination of serum total cholesterol (Young, 2001) & triglycerides (Stein, 1987). High density lipoprotein (HDL-C) measured by enzymatic colorimetric method using Randox kits (Gordon, 1977). The concentration of low-density lipoprotein (LDL-C) cholesterol was calculated as follows.

LDL-cholesterol (mg-dl) = total cholesterol (T.C) – HDL cholesterol –

triglyceride (TG)

5

2.7. Histology: Liver, heart and pancreas tissues from the sacrificed rats were sliced to a thickness of 3 mm and arranged in a tissue cassette with attached label. The tissues were processed using an automated tissue processor according to (Drury and Wallington 1980).

2.8. Statistical analysis.

The obtained results were analyzed using SD--Duncan's new multiple range test which was used to determine the significant difference of means at $P \leq 0.05$ (Steel and Torrie,1980).

3. Results and Discussion

3.1. Composition of raw materials.

Chemical composition of wheat, oat, peanut skin and bran flour are presented in table (1).It could be observed that peanut skin flour possessed the highest values of flour in protein, fat and crude fiber .Bran flour occupied the second position in fat and crude fiber constituents. In addition oat flour was characterized by its content of protein .These results are in agreement with at obtained by Carison *et al.*, (1981) and Hammad (2007).

Table (1): Chemical composition % of raw materials

Samples	Moisture%	Crude protein %	Crude fat %	Crude fiber%	Ash %	Total carbohydrate %
Wheat flour	11.37	9.19	0.91	0.90	0.34	77.29
Oat flour	9.50	14.30	3.05	9.18	1.94	62.03
Peanut skin flour	7.86	15.36	15.28	13.23	2.80	45.47
Bran flour	10.46	11.40	6.89	11.93	3.66	55.66

3.2. Chemical composition of dietary fiber rich biscuits.

Data in table (2) indicated that the mixture of oat and peanut skin biscuit (BOPs) had the highest content of crude fiber (15.92) followed by peanut skin biscuit (15.63) ,oat biscuit (14.07) and the commercial one (1.84). Although oat-peanut skin and oat biscuits had the highest protein contents, Commercial biscuit (BC) was the highest in fat content (19.96). These date are agreed with previous studies. The protein content of biscuits in rich dietary fiber was slightly higher as compared to the reported protein content of the commercial biscuits (8.7) (Tyagi *et al.*, 2007) . Crude fiber and total ash content were found to increase with increasing in the proportion of pigeon pea flour. Hooda and Jood (2005) also, reported that an increase in the fiber content of biscuits by incorporation of fenugreek flour. Tyagi *et al.*, (2007) reported that an increase in fiber content by incorporation of defatted mustard flour.

Table (2): Chemical composition of commercial, oat, peanut skin, and oat –peanut skin biscuits

Biscuit Sample	Moisture %	Crude protein %	Crude fat %	Crude fiber %	Ash %	Total carbohydrate %
Bc	5.5	8.7	19.96	1.84	1	63
BO	8.03	10.08	3.09	14.07	2.00	62.73
BPs	9.83	9.33	9.20	15.63	3	53.01
BOPs	8.09	10.50	6.79	15.92	3.3	55.40

BC: Biscuit commercial, BO: Biscuit oat, BPs: Biscuit skin peanut, BOPs: Oat and peanut skin biscuit

3.3. Organoleptic properties of dietary fiber rich biscuits.

Organoleptic properties scores of commercial (BC), oat (BO), peanut skin (BPs), and oat –peanut skin biscuits (BOPs) are show in table (3) as the organoleptic properties(color ,flavor ,texture ,taste ,mouth feeling, overall acceptability) were indicated in this table. It could be noticed that peanut skin biscuits possessed the lowest scores in all sensory properties. Meanwhile commercial biscuits recorded the highest scores. The overall acceptability of commercial biscuits which recorded the highest level followed by oat and peanut skin, then the oat biscuits respectively. These results are in line with at found by **Hammad (2007)**.

Table (3): Organoleptic properties of commercial (BC), oat (BO), peanut skin (BPs), and oat –peanut skin biscuits (BOPs)

Biscuit properties	COLOR (10)	FLAVOR (10)	TEXTURE (10)	TASTE (10)	MOUTH feeling (10)	Overall acceptability (90)
Commercial biscuit (BC)	9.38a	8.75a	8.88a	8.63a	9.13a	82.50a
Oat biscuit(BO)	8.88a	8.13ab	7.50bc	8.25a	7.88b	76.88a
Peanut skin biscuit(BPs)	8.38a	6.88b	6.25c	6.13b	6.75b	62.63b
Oat and peanut skin biscuit(Bops)	8.50a	8.25a	8.00ab	7.63ab	6.88b	80.75a
L.S.D : $p \leq 0.05$	1.31	1.26	1.19	1.68	1.19	12.0

BC :Biscuit commercial , BO: Biscuit oat, BPs :Biscuit skin peanut, BOPs: Oat and peanut skin biscuit

$p \leq 0.05$:Means with different letters (a,b,c,etc.) in the same colum differs significantly at $p \leq 0.05$ using Duncan Range Multiple Test ,while those with similar letters are non-significantly different .

3.4. Effect of feeding commercial and dietary fiber rich biscuits on the body weight (g) of rats.

The effects of various biscuits types on the body weight change of rats during 12 weeks were reported in table (4). The results showed decreasing in the weights of rats fed on peanut skin and oat biscuits compared to commercial biscuits. Weights of animals were decreased after feeding of high dietary fiber biscuit comparing to control and commercial biscuit. On the same trended, **Peng, et al., 2012** mentioned that oat reduced body weight at 4 week, all the high fat diet fed rats increased more than 30% of the body weight when compared with the control. Oat inhabited the body weight gain, and apparently showed the effect markedly after oat treatment for 6 weeks. In comparison with metabolized energy and feed intake, the reduction of body weight and fat deposition was not associated with appetite or energy intake. Hence, the anti-obesity effect of oat could be attributed to metabolic regulation.

Table (4):Effect of feeding biscuit on the body weight of rats

Feeding time treatments	Weeks and weight (g)rats				L.S.D: p≤0.05
	2	4	8	12	
OC(control)	220.00a	214.33a	219.33a	222.00a	18.51
OBC	220.00a	225.00a	230.33a	240.00a	24.30
OBO	220.00a	210.67a	200.00a	190.00b	24.37
OBPs	220.00a	205.67a	193.67a	180.00b	21.48

OC (control) :normal group (untreated),OBC : obesity Biscuit commercial ,OBO : obesity Biscuit Oat, OBPs: obesity Biscuit peanut skin .

3.5. Effects of feeding biscuit on blood glucose of rats.

Glucose is the major energy source of cells. Stable blood glucose is necessary since energy must be supplied to all cells at all times despite intermittent food intake and variable demands, such as the level of physical activity (Marks and Raskin 2000) . Effects of biscuit feeding on blood glucose of rats suffering of obesity and diabetes are shown in table (5,a,b) .The results after 4,8,12 weeks showed decreasing in blood glucose level for biscuit–oat (OBC)&oat –peanut skin biscuits in comparison control and commercial biscuit groups.

The observed hypoglycemic and antioxidant activities of *Cydonia oblonga* leaves and *Allium porrum bulbs* might be related to the coumarins (scopoletin),tannins, terpenoids, and flavonoids contents. *Cydonia oblonga* leaves and *Allium porrum bulbs* can be used by diabetic patients to decrease complications of diabetes. Especially, long term remedy with *Cydonia oblonga* leaves can be useful for people with Type II diabetes mellitus (Mustafa *et al.*, 2010). Oat could act as adjuvant therapeutic for metabolic disorders via attenuating obesity, body fat, and improving serum parameters with metabolic regulation and lipid clearance of liver, and oat lowered serum glucose, free-fatty-acid (FFA), triacylglycerol (TG), cholesterol, and LDL-C/HDL-C elevated by (high fat diet) HFD, and dose-dependently reduced hepatic TG and cholesterol (Chiung-Huei *et al.* 2012).

Table (5,a) Effect of feeding biscuit on blood glucose of obese rats

Groups	weeks			
	2	4	8	12
OC	135.91c	132.18a	100.5d	131.04b
OBC		150.49a	140.7b	142.91d
OBO		121.53b	106.93d	110.23c
OBPs		120.52b	112.87b	103.84c
LS.D: $p \leq 0.05$	1.36	1.45	1.32	1.58

OC (control): normal group (untreated) ,OBC: obesity Biscuit commercial , OBO: obesity Biscuit Oat, OBPs: obesity Biscuit peanut skin .

Table (5,b) Effect of feeding biscuit on blood glucose of rats diabetes.

Groups	weeks			
	2	4	8	12
DBC	299.4a	237.12b	280.45b	300.23c
DBO		274.16d	212.87c	114.85b
DBPs		273.76b	193.96d	110.89c
DBOPs		260.81c	192.01d	117.62b
LS.D: $p \leq 0.05$	1.56	1.63	1.83	1.50

DBC: diabetic rats biscuit commercial

DBO : diabetic + high dietary fiber biscuits (oat biscuit)

DBPs : diabetic + high dietary fiber- biscuits (peanut skin biscuit)

DBOPs : diabetic + high dietary fiber biscuits(peanut skin and oat biscuit)

3.6.Effect of feeding dietary fiber rich biscuits on obesity blood rats.

The results in table (6) show that significant difference was observed in all studied groups expect at zero time and a lower level of total cholesterol (TC), triglyceride(TG)and low density lipoprotein (LDL) observed in the peanut skin biscuits groups followed to oat biscuit. The peanut skin biscuits group had lowest content of serum cholesterol, TG, LDL and higher HDL levels, after four weeks in feeding of the rich dietary fiber biscuit. Feeding on peanut skin and oat biscuit reduced total cholesterol and triglyceride blood rats obesity . Several studies have associated fiber intake with higher levels of HDL and lower LDL in the blood (Spiller,1993). Nest,(2005) proposed that this is due to increase

generation of propionate, which has been shown to reduce cholesterol levels and inhibit cholesterol synthesis. Oat bran decreased the total cholesterol level in serum, and decreased the cholesterol and TG contents in the liver (Grajeta , 1999). Compared with the other gums, oat effectively reduced both the serum and hepatic lipids (Oda *et al.*, 1994). Oat lowered serum glucose, TG, cholesterol and free-fatty-acid (FFA) which were enhanced by high-fat-diet (HFD). With increasing HDL and decreasing LDL, oat improved the lipoprotein profiles of LDL-C/HDL-C (Peng, *et al.*, 2012).

Table (6) :Effect of feeding high dietary fiber biscuits on serum lipid profile in obesity rats

Feeding periods (weeks)	Treatments	Total cholesterol (mg-dl)	Triglyceride (mg-dl)	HDL (mg-dl)	LDL (mg-dl)
Zero Time	OC	149.15a	270.69a	65.68a	49.33a
	OBC				
	OBO				
	OBPs				
L.SD:	$p \leq 0.05$	0.28	1.30	0.15	0.62
4 week	OC	112.15c	198.38b	59.33c	13.60b
	OBC	136.17b	219.35a	65.70a	26.60b
	OBO	140.07a	192.43d	63.06b	38.49a
	OBPs	110.68d	190.95c	66.31b	35.18d
L.SD:	$p \leq 0.05$	0.68	1.08	0.79	0.78
8 week	OC	137.08c	231.45a	67.52b	23.27c
	OBC	141.91a	223.38b	69.01b	49.33b
	OBO	139.84b	195.96c	65.03c	35.62a
	OBPs	138.69b	196.87c	69.70a	30.02b
L.SD:	$p \leq 0.05$	1.34	1.34	0.82	0.71
12 week	OC	140.3b	235.39a	62.10d	31.52b
	OBC	144.78a	235.89a	64.04c	33.56a
	OBO	135.59d	194.96b	66.17b	30.43c
	OBPs	132.59d	193.96b	79.09a	14.71a
L.SD:	$p \leq 0.05$	0.99	3.90	0.21	0.99

OC (control) :normal group (untreated) OBC : obesity Biscuit commercial
 OBO : obesity Biscuit Oat OBPs: obesity Biscuit peanut skin .

3.7. Effect of feeding high dietary fiber biscuits on diabetic blood rats.

Values of biochemical parameters in table (7) show that the high dietary fiber biscuits were revealed the highest levels of high density lipoprotein (HDL)and the lowest level of total cholesterol ,

triglyceride(TG), and low density lipoprotein(LDL) as compared with commercial biscuit starting in the eight week . The low values observed for dietary fiber biscuit-fed groups considering serum cholesterol, TG, LDL, with high HDL levels, after 8 weeks feeding.

The vast majority of epidemiological and intervention studies show that high fiber diets help improve glycemic control and reduce the need for insulin in diabetic subjects.(**National Academy of Sciences (2005)**).

It was reported that high beta-glucan contained oat bran and oat gum which reduced postprandial serum glucose and insulin in both the control and type 2 diabetic subjects (**Braaten et al., 1994**). In streptozotocin-induced diabetic mice, oat significantly decreased fasting blood glucose, glycosylated protein, and free fatty acid content, while inhibited pancreatic apoptosis (**Shen et al., 2011**).

Table (7):Effect of feeding high dietary fiber biscuits on serum lipid profile of diabetic rats.

Feeding period (week)	Treatments	Total cholesterol (mg-dl)	Triglyceride (mg-dl)	HDL (mg-dl)	LDL (mg-dl)
Zero Time	DBC	170.64a	154.28a	55.06a	78.7a
	DBO				
	DBPs				
	DBOPs				
L.SD: $p \leq 0.05$		0.27	1.13	0.15	0.60
4 week	DBC	139.83ab	108.81c	27.55e	90.38a
	DBO	140.41a	107.63c	40.19d	78.77b
	DBPs	137.54c	111.94b	64.25a	60.9d
	DBOPs	137.23b	110.01b	42.17c	71.06c
L.SD: $p \leq 0.05$		0.90	1.21	0.60	01.0
8 week	DBC	141.11a	124.57b	40.01d	76.19b
	DBO	141.21a	100.12e	48.67e	55.72d
	DBPs	141.22a	111.12c	63.26b	72.52a
	DBOPs	130.86c	105.4d	50.75c	59.03c
L.SD: $p \leq 0.05$		0.75	0.71	0.95	0.77
12 week	DBC	142.36a	140.33b	44.26a	51.04c
	DBO	139.61b	114.6b	65.7e	44.99a
	DBPs	135.96c	110.91b	59.76c	53.08b
	DBOPs	123.54d	102.77d	60.3d	43.69d
L.SD: $p \leq 0.05$		1.09	3.45	0.90	01.07

DBC : diabetic rats Biscuit commercial

DBO : diabetic + high dietary fiber biscuits (Oat Biscuit)

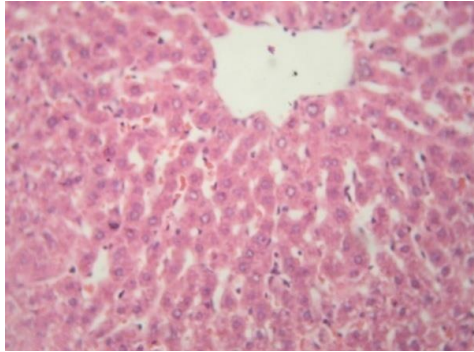
DBPs : diabetic + high dietary fiber- biscuits (peanut skin Biscuit)

DBOPs :diabetic + high dietary fiber biscuits(peanut skin and Oat Biscuit)

Histopathological changes of obesity.

Histological examination of the experimental rats liver, heart ,and pancreas is shown in photos (1.to 9) for obesity experiments.

O C group :Normal group (Untreated):



hoto.(1): Liver control group showing normal hepatic parenchyma (H & E x1200)

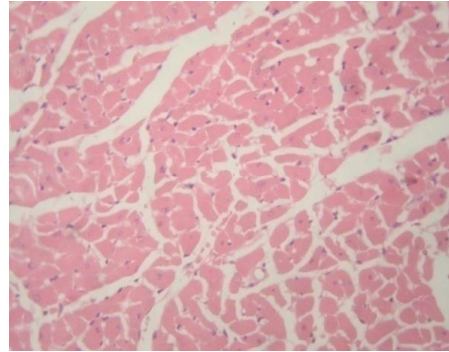


photo.(2): Heart control group showing normal myocardium(H&E x1200)

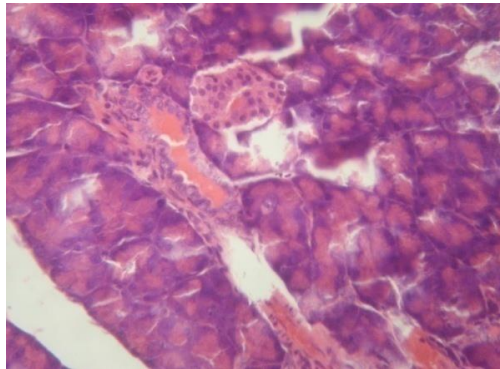


photo.(3):Pancreas control group showing normal endocrine and exocrine pancreas(H & E x1200).

It was formed that for liver the hepatic parenchyma, mainly the hepatic cords, sinusoids and kupffer cells were morphologically normal rat (photo.1).For heart the myocardial muscle fibers were apparently normal rat (photo 2). Also for pancreas the components of this organ pancreas including the endocrine & exocrine portions were microscopically normal rat (photo 3).

OBC group : Commercial biscuit group:

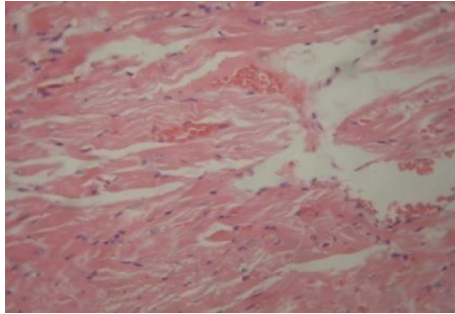


photo.(4):Liver of (OBC) group showing severe steatosis of all the hepatic lobules(H & E x300).

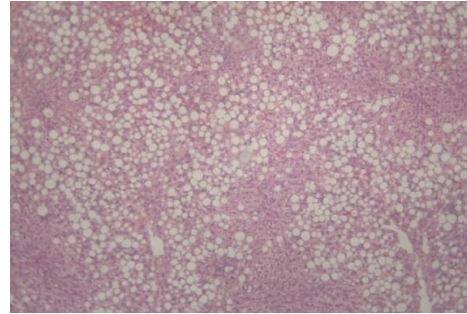


photo.(5): Heart of (OBC) group showing artial hyaline degeneration and dilated blood vessels(H & E x300).

For commercial biscuit groups the majority of hepatic cells suffered from steatosis manifested by clear & sharp vacuoles of variable sizes replacing the cytoplasm with dislocated nuclei (photo.4) and steatosis was random in distribution among the hepatic lobules; the remaining hepatic cells revealed various types of cell injuries mainly acute cell swelling. For heart all of the myocardial muscle fibers were swollen with partial hyaline degeneration besides dilated inter muscular blood vessels with capillaries and a few pyknotic nuclei (photo.5)

OBO group (oat biscuit):

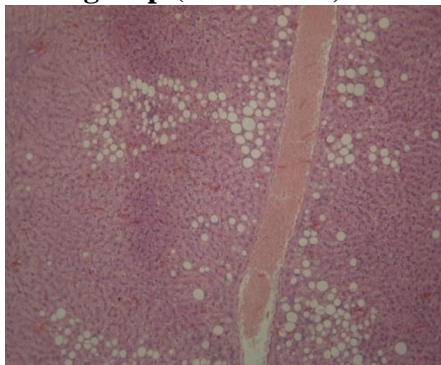


photo.(6): liver of (OBO) group showing focal periphery lobular steatosis(H & E x300)

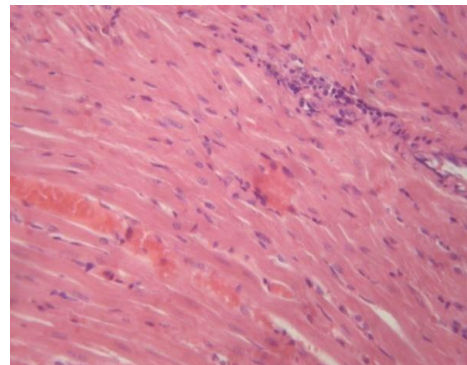


photo.(7): Heart of (OBO) group showing cloudy swelling and focal mononuclear cell infiltration(H & E x1200).

Section of the liver showed focal periphery lobular steatosis with mild degenerative changes in some hepatic cells which were the common changes in the hepatic tissue (photo.6).Mean while sections of

heart indicated that the myocardium showed cloudy swelling, congested blood vessels and a few mononuclear cell infiltration among some muscle fibers (photo.7) .

OBP's group :(Peanut skin biscuit) :

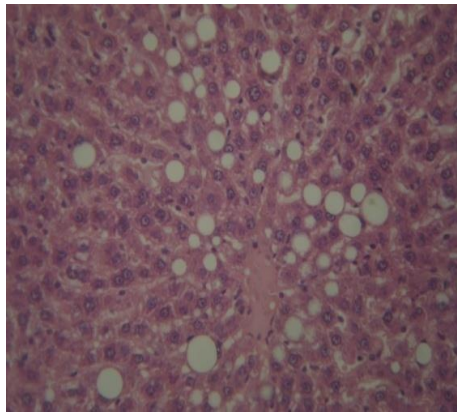


photo.(8): liver of (OBPs) group showing mild changes of scattered hepatic cells (H & E x300).

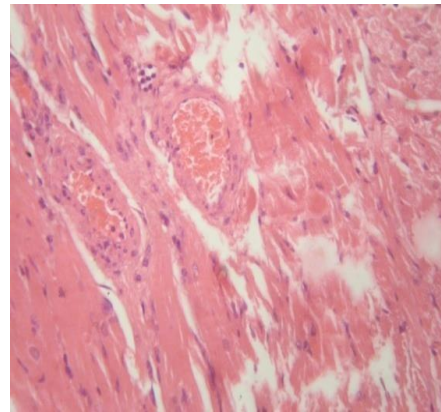


photo.(9): Heart of (OBPs) group showing mild inter and intramuscular edema (H & E x300).

It is evident that some scattered hepatic cells have clear vacuoles of variable sizes suggestive steatosis with pyknotic nuclei located mainly on the periphery of the affected cells together with mild reversible degenerative changes in the remaining hepatic cells and hypertrophied kupffer cells (photo.8).Heart sections revealed mild inter and intramuscular edema, partial hyalinization, congested blood vessels and few lymphocyte infiltration (photo.9).

It showed be noted that *Chiung-Huei et al., (2012)* indicated that high-fat-diet(HFD) increased liver cholesterol and TG by 3.2 and 2.8 folds, respectively. Supplement of oat reduced the hepatic lipids changes dose-dependently. HFD with 7.5%, 15% and 30%oat decreased liver cholesterol by 13%, 33%, and 41% and liver TG by 30%, 34% and 47%, respectively. This showed the reduction of fatty metamorphosis on livers of oat supplemented rats. Histopathological investigation confirmed the biochemical results .

Histopathological changes of diabetic experiments .

DBC group : (Commercial biscuit group):

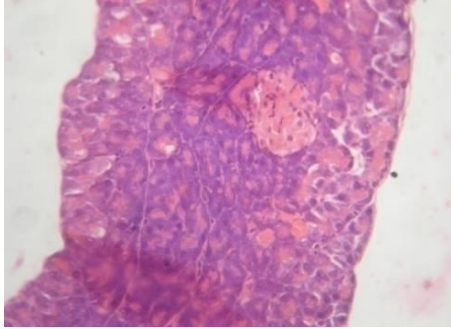


photo.(10): Pancreas of (DBC) group showing programmed or accidental cell death of endocrine pancreas (H & E x1200).

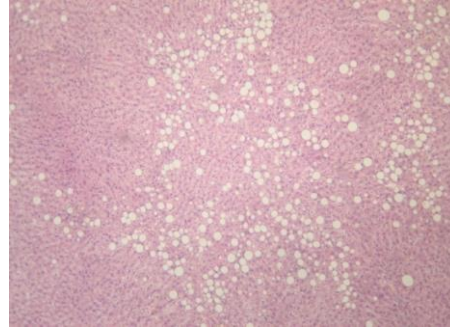


photo.(11): Liver of (DBC) group showing random steatosis of some hepatic cells (H & E x300).

Pancreas section indicated that the cells of endocrine pancreatic portion suffered either from programmed or accidental cell death (photo.10). Islets of Langerhans were shrunk and less cellular with loss of secretory activity .Section of the liver some hepatic cells exhibited different types of cell injuries mainly steatosis (photo.11). The latter lesion was focally distributed and involves all the hepatic lobular zones, besides mild thickened interlobular septa with fibrous tissue. Other hepatic cells appeared either normal or revealed mild degenerative changes varied from vacuolar to hydrobic degeneration .

DBO group : (Oat biscuit group) :

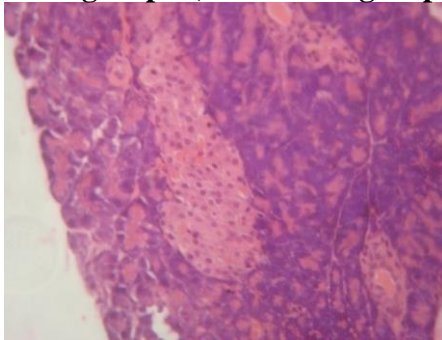


photo.(12): Pancreas of (DBO) group showing a few cells of endocrine pancreas suffering from necrosis (H & E x1200).

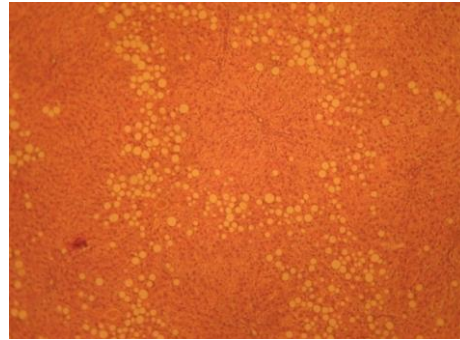


photo.(13): Liver of (DBO) group showing steatosis in a few cells and normal remaining hepatic cells (H & E x300) .

Pancreas sections showed few cells of endocrine pancreas had pyknotic nuclei, the remaining cells were apparently normal (photo.12). Islets of Langerhans were of normal size regardless of that the exocrine

activity of pancreas was less active. Section of Liver indicated mild changes in some hepatic cells, mainly steatosis, which usually confined to the prephery lobular zones of some hepatic lobules, and the remaining cells were apparently normal (photo.13). Some portal areas had mild lymphocytic infiltration.

DBPs group : (Peanut skin biscuit group):

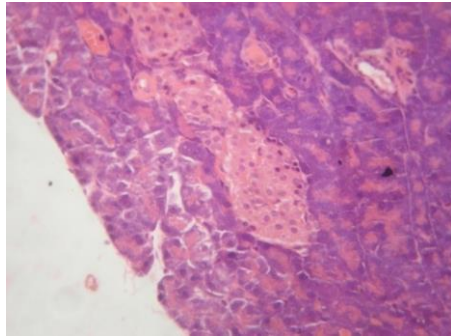


photo.(14) :Pancreas of (DBPs) group showing pyknotic nuclei of some endocrine cells (H & E x1200).

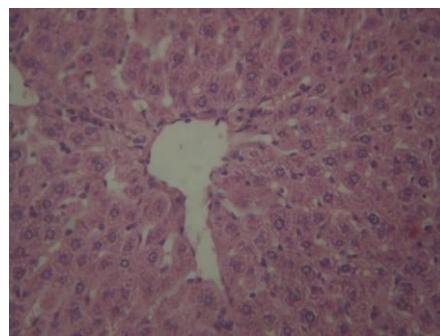


photo.(15): Liver of (DBPs) group showing acute cells swelling(H & E x1200).

Section of pancreas illustrated few scattered cells in Islets of Langerhans had pyknotic nuclei and others were degenerated together with moderate activities in exocrine portion being the common findings (photo.14).Also, liver section ,revealed mild reversible lesions, mainly acute cell swelling with hyperplastic kupffer cells which were the common microscopical changes (photo.15).

DBOPs group : (Oat and Peanut skin biscuit group):

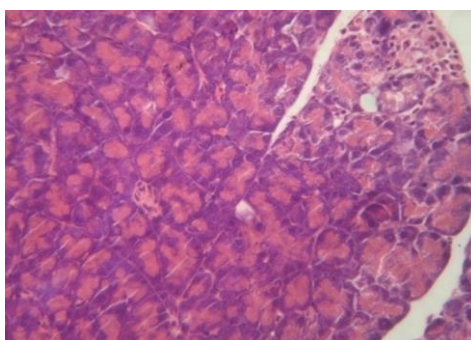


photo.(16): Pancreas of (DBOPs) group showing necrotic endocrine pancreas infiltrated with lymphocytes (H & E 1200).

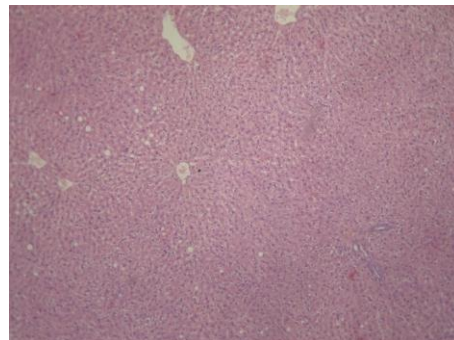


photo.(17): Liver of (DBOPs) group showing apparently normal hepatic cells and minimal cells with steatosis (H & E x300).

Investigation of pancreas sections showed degenerated and necrotic cells which sometimes infiltrated with lymphocytes (photo.16). The cells of pancreatic acini were highly active and distended with secretion. Section of liver indicated few scattered hepatic cells still contain minute vacuoles of steatosis, and others were apparently normal together with numerous bile ductless in some portal areas (photo.17).

There have been a several recent reports concerning fat accumulation and steatosis in the livers of rats and mice fed with high fat diet (*Par et al., 2005; Huang et al., 2006; Guo et al., 2008*). Liver fat accumulation is associated with insulin resistance, which is supported by the fact that a decrease in hepatic fat is accompanied by improvements in insulin sensitivity and splanchnic glucose uptake (**Kahn and Flier, 2000; Samuel et al., 2004**). In this study, results found severe hepatic steatosis in rats was found belonging to the diabetic control group, which was in accordance with previous reports (**Par et al., 2005; Huang et al., 2006; Guo et al., 2008**). There was a significant decrease in liver fat accumulation in the high dietary fiber biscuit compared with the commercial biscuit group as fed to diabetic groups.

The fiber enriched biscuits had a therapeutic protective effect against diabetes induced toxicit in brain tissue of rats. The synergetic effect resulted relatively from reduced lipid peroxidation products which decreased dyslipidemia , and increased antioxidant activities (**Ochuko Erukainure et al., 2012**).

Conclusion

Feeding on rich dietary fiber biscuits reduced obesity and had antidiabetic potential as evidenced by reduced blood glucose and improved serum insulin and increased high-density-lipoprotein cholesterol levels. Biscuits Rich dietary fiber was a sensorial acceptable products with enhanced nutritional and bio-functional properties and proved to be beneficial healthy.

References :

- Ajila, C.M.; Leelavathib, K. and Prasada, .U.J.S. (2008)**
:Improvement of dietary fiber content and antioxidant properties in soft dough biscuits with the incorporation of mango peel powder .
Journal of Cereal Science ,48:319-326.

- Anderson, J. W.; Spencer, D. B.; Hamilton, C.C., Smith, S. F.; Tietyen, J. and Bryant, C. A., et al., (1990).** Oat-bran cereal lower serum total and LDL cholesterol in hypercholesterolemia men. *American Journal of Clinical Nutrition*, 52(3): 495–499.
- AOAC, (2001):** Official Methods of Analysis of the Association of Official Analytical Chemists . 15thE.d., Washington, D.C., U.S.A.
- Aslan, M.; Deliorman Orhan, D. ; Orhan, N. ; Sezik, E. ; and Yesilada, E., (2007a):** In vivo and diabetic and antioxidant potential of *Helichrysum plicatum ssp. Plicatum capitulum* in streptozotocin-induced diabetic rats. *Journal of Ethnopharmacology*, 109: 54–59.
- Aslan, M. ; Deliorman Orhan, D. ; Orhan, N. ; Sezik, E. ; and Yesilada, E., (2007b):** A study of antidiabetic and antioxidant effects of *Helichrysum ssp. Graveolens capitulum* in streptozotocin-induced diabetic rats. *Journal of Medicinal Foods*, 10: 396–400.
- Balasubramanian, R. ; Kasiappan, R.; Vengidusamy, N.; Muthusamy, K. and Sorimuthu, S. (2004):** Protective effect of macrocyclic binuclear oxovanadium complex on oxidative stress in pancreas of streptozotocin induced diabetic rats. *Chemico-Biological Interaction*, 149: 9–21.
- Block, G. and Langseth, L. (1994):** Antioxidant vitamins and disease prevention. *Food Technology*, 48: 80-84.
- Braaten, J. T. ; Scott, F.W. ; Wood, P. J. ; Riedel, K. D. ; Wolynetz, M. S. ; Brule, D. and Collins, M. W. (1994):** High beta-glucan oat bran and oat gum reduce postprandial blood glucose and insulin in subjects with and without type 2 diabetes. *Diabetic Medicine*, 11: 312–318.
- Calle, E. E. ; Thun, M. J. ; Petrelli, J. M. ; Rodriguez, C. and Heath, C. W.J. (1999):** Body-mass index and mortality in a prospective cohort of U.S. adults. *The New England Journal of Medicine*, 341: 1097–1105.
- Carison, B.L. ; Knorr, D. and Watkins, T.R. (1981):** Influence of tomato seed addition on the quality of wheat flour bread. *J. Food Sci.*, 46: 1029-1031.

- Chakraborty, U. and Das,H. (2010):** Ant diabetic and antioxidant activities of *Cinnamo-mum tamala* leaf extracts in STZ-treated diabetic rats. *Global Journal of Biotechnology & Biochemistry*,5:12–18.
- Chiung-Huei P.: I.; Hong-Chou,C.: Mon-Yuan Y.; Chien-Ning,H.D.; Shing-Jung, W. and Chau-Jong, W. (2012):** Oat attenuate non-alcoholic fatty liver and obesity via inhibiting lipogenesis in high fat-fed rat *Journal of Fuctional Foods*,5 (1):53-61.
- Davy, B.M. ; Davy, K.P. ; Ho, R.C.; Beske, S.D.; Davrath, L.R. and Melby, C.L. (2002):** High-fiber oat cereal compared with wheat cereal consumption favorably alters LDL-cholesterol subclass and particle numbers in middle-aged and older men. *American Journal of Clinical Nutrition*, 76(2): 351–358.
- Despres, J.P. (2006):** Is visceral obesity the cause of the metabolic syndrome? *Annals of Medicine*, 38: 52–63.
- [Diederick, M.](#) (2015):** Chapter Two – Health Benefits of Prebiotic Fibers (chapter Two).Available online 7 January 2015.47.74-91.
[About this Book Series:](#) Advances in Food and Nutrition Research.
- Druvy ,R.A and Wallingyen ,E.A.(1980):**Cartons Histological Technique 5th Ed. Oxford Univ.
- Gallagher, E.; O'Brien, C.M.; Scannell, A.G.M. and Arendt, E.K. (2003):** Use of response surface methodology to produce functional short dough biscuits. *Journal of Food Engineering*, 56: 269–271.
- Gandhi, A.P.; Kotawaliwale, N.; Kawalkar, J.; Srivastava, D.C.; Parihar, V.S. and RaghuNadh, P. (2001):** Effect of incorporation of defatted soy flour on the quality of sweet biscuits. *Journal of Food Science and Technology*, 38: 502-503.
- Grajeta, H. (1999):** Effect of amaranth and oat bran on blood serum and liver lipids in rats depending on the kind of dietary fats. *Nahrung*, 43: 114–117.
- Gordon, T.M. (1977):** HDL-Cholesterol determination after separation higher density lipoprotein lipid. *Amer. J. Med.*, 62: 707.

- Guo, Z.Y. ; Bu, S.Z. ; Yu, Y.W. and Gautam, G. (2008):** Diazoxide prevents abdominal adiposity and fatty liver in obese OLETF rats at prediabetic stage. *Journal of Diabetes and Its Complications*, 22: 46–55.
- Hammad A.A. (2007):** Production of protein fortified biscuit with defatted tomato seed meal .*Egyptian J.of Nutrition* ,22 (2): 121-139.
- Hemalatha, S. ; Wahi, A.K. ; Singh, P.N. and Chansouria, J.P.N. (2004):** Hypoglycemic activity of *Withania Ceoaculants*,Dunal in streptozotocin induced diabetic rats. *Journal of Ethnopharmacolgy*, 93: 261–264.
- Hooda, J. and Jood, S. (2005):** Organoleptic and nutritional evaluation of wheat biscuits supplemented with untreated and treated fenugreek flour. *Food Chemistry*, 90: 427–435.
- Huang, H.W.; Peng, G. ; Li, Q. ; Yamahara, J. ; Roufogalis, B.D.and Li, Y.H. (2006):** *Salacia oblonga* root improves postprandial hyperlipidemia and hepatic steatosis in Zucker diabetic fatty rats: Activation of PPAR- α . *Toxicology and Applied Pharmacology*, 210: 225–235.
- Maki, K. C. ; Beiseigel, J. M. ; Jonnalagadda, S.S. ; Gugger, C.K.; Reeves, M.S. ; Farmer, M.V. ; Kaden, V.N. and Rains, T.M. (2010):** Whole-grain ready-to-eat oat cereal, as part of a dietary program for weight loss, reduces low-density lipoprotein cholesterol in adults with overweight and obesity more than a dietary program including low-fiber control foods. *Journal of the American Dietetic Association*, 110: 205–214.
- Maria, L.L. (2009a):** Total phenolics and antioxidant capacity of heat treated peanut skins. *Journal of Food Composition and Analysis* , 22: 16-24.
- Maria,L.L. (2009b):** Development of a reversed-phase high performance liquid Chromatography (RP-HPLC) procedure for the simultaneous determination of phenolic compounds in peanut skins extracts. *Food Chemistry*, 117: 356-363.

- Maritimi A.C. ;, Sanders R. A. and Watkins, J.B. (2003):** Diabetes, oxidative stress, and antioxidants: A review. *Journal of Biochemical and Molecular Toxicology*, 17: 24–38.
- Marks J.B. and Raskin P: (2000).** Cardiovascular risk in diabetes. A brief review. *J Diab. Complications*, 14 (2):108-115.
- Mustafa A.; Nilüfer, O.; Didem, D.O. and Fatma, E. (2010):** Hypoglycemic activity and antioxidant potential of some medicinal plants traditionally used in Turkey for diabetes. *Journal of Ethnopharmacology*, 128: 384–389.
- Najafian, M. (2014):** A review of α -amylase inhibitors on weight loss and glycemic control in pathological state such as obesity and diabetes. *Comp. Clin .Pathol .*, Received: 23 May 2014 /Accepted: 25 June 2014. # Springer-Verlag London .DOI 10.1007/s00580-014-1967-x 2014. e-mail: d.najafian@jia.ac.ir.
- National Academy of Sciences (2005):** Dietary, functional, and total fiber. In: *Dietary Reference Intakes for Energy, Carbohydrates, Fiber, Fat, Fatty acids, Cholesterol, Protein, and Amino Acids*. Washington, DC: National Academies Press [Chapter 7].
- Natalia, R.S.; Kaisa, P. and Valérie, M. (2015):** How does wheat grain, bran and aleurone structure impact their nutritional and technological properties?. *Trends in Food Science & Technology*, 41:118-134.
- Nesto, R.W. (2005):** Beyond low-density lipoprotein: Addressing the atherogenic lipid triad in type 2 diabetes mellitus and the metabolic syndrome. *American Journal of Cardiovascular Drugs* 5,(6):379–87.
- Oda, T. ; Aoe, S.; Imanishi, S.; Kanazawa, Y.; Sanada, H. and Ayano, Y. (1994):** Effects of dietary oat, barley, and guar gums on serum and liver lipid concentrations in diet-induced hypertriglyceridemic rats. *Journal of Nutritional Science & Vitaminology*, 40: 213–217.
- Ochuko L. Erukainurea, B.D. ; Osaretin A.T. E. ; Folasade, O. A.; Ebele, N. O.; Aliyu, M. and Gloria N.E. (2013):** Fiber-enriched biscuit enhances insulin secretion, modulates b-cell

function, improves insulin sensitivity, and attenuates hyperlipidemia in diabetic rats. *Pharma Nutrition* 58–64 Journal. homepage: www.elsevier.com/locate/phanu.

- Par, S.; Nir, R. ; Reut, B.S.; Walker, M.D. and Helena, E. (2005):** The FFA receptor GPR40 links hyperinsulinemia, hepatic steatosis, and impaired glucose homeostasis in mouse. *Cell Metabolism*, 1: 245–258.
- Peng, C.H. ; Hong, C. ; Mon-Yuan, Y. ; Chien-NingHuang, B.D. ; Shing-Jung W. and Chau-Jong W.F. (2012):** Oat attenuate non-alcoholic fatty liver and obesity via inhibiting lipogenesis in high fat-fed rat. *Journal of Functional Foods*. <http://dx.doi.org/10.1016/j.jff.2012.08.003>.
- Polikandrioti, M. and Dokoutsidou, H. (2009):** The role of exercise and nutrition in type II diabetes mellitus management. *Journal of Health Science*, 3(4): 216–21.
- Queenan, K.M. ; Stewart, M.L. ; Smith, K.N. ; Thomas, W. ; Fulcher, R.G. and Slavin, J.L. (2007):** Concentrated oat beta-glucan, a fermentable fiber, lowers serum cholesterol in hypercholesterolemic adults in a randomized controlled trial. *Nutrition Journal*, 6: 6.
- Reyna-Villasmil, N. ; Bermudez-Pirela, V. ; Mengual-Moreno, E. ; Arias, N. ; Cano-Ponce, C. ; Leal-Gonzalez, E. ; Souki, A. ; Inglett, G.E. ; Israili, Z. H. ; Hernandez-Hernandez, R. ; Valasco, M. and Arraiz, N. (2007):** Oat-derived beta-glucan significantly improves HDLC and diminishes LDLC and non-HDL cholesterol in overweight individuals with mild hypercholesterolemia. *American Journal of Therapeutics*, 14: 203–212.
- Shaw, J.E. ; Sicree, R.A. and Zimme, P.Z. (2010):** Global estimates of the prevalence of diabetes for 2010 and 203. *Diabetes Research and Clinical Practice*, 87: 4–14.
- Shen, R.L. ; Cai, F.L. ; Dong, J.L. and Hu, X.Z. (2011):** Hypoglycemic effects and biochemical mechanisms of oat

products on streptozotocin-induced diabetic mice. *Journal of Agricultural and Food Chemistry*, 59: 8895–8900.

Stein, E.A. (1987): Lipids, Lipoproteins, and Apo-lipoproteins. In: Tietz NW, Ed. *Fundamentals of Clinical Chemistry*. 3rd Ed. Philadelphia: WB Saunders, 448-481.

Steel, R.G.D. and Torrie, J.H. (1980): Principles and Procedures of Statistics. McGraw, New York.

Tiwari, B.K.; Brennana, C.S. ; Jaganmohanb, R. ; Surabib, A. and Alagusundaramb, K. (2011): Utilisation of pigeon pea (*Cajanuscajan L*) byproducts in biscuit manufacture LWT. *Food Science and Technology*, 44 : 1533-1537.

Tyagi, S.K. ; Manikantan, M.R. ; Harinder, S. O. and Kaur, G. (2007): Effect of mustard flour incorporation on nutritional, textural and organoleptic characteristics of biscuits. *Journal of Food Engineering*, 80: 1043–1050.

Vitali, D. ; Vedrina, D. and Sebecic, B. (2009): Effect of incorporation of integral raw materials and dietary fiber on the selected nutritional and functional properties of biscuits . *Journal Food Chemistry*, 114: 1462-1469.

Wang, S.Y. and Jiao, H. (2000): Scavenging capacity of berry crops on superoxide radicals, hydrogen peroxide, hydroxy radicals and singlet oxygen. *Journal of Agricultural and Food Chemistry*, 48: 56 77e-56 84e.

Wild, S. ; Roglic, G. ; Green, A. ; Sicree, R. and King, H. (2004): Global prevalence of diabetes estimates for the year 2000 and projections for 2030. *Diabetes Care*, 27: 1047–1053.

Young, D.S. (2001): Effects of Disease on Clinical Lab. Tests. 4th Ed., AACC.

السمنة والبول السكري في تأثير البسكويات الغنية بالألياف الغذائية على الفران

حنان سعيد شلبي - جيهان عبدا لله الشوربجي

قسم علوم الأغذية (شعبة اقتصاد منزلي ريفي) - كلية الزراعة - جامعة الزقازيق¹، أستاذ مساعد الصناعات الغذائية - قسم علوم الأغذية - كلية الزراعة - جامعة الزقازيق²

الملخص:

تم اختيار البسكويات الغنية بالألياف من الشوفان وقشور السوداني لما لها من خواص تغذوية وعلاجية وباستهلاك هذه المكونات ذات النشاط الحيوي الطبيعية وجد أن لها فوائد صحية عديدة بما في ذلك الوقاية من أمراض القلب والأوعية الدموية. الدراسة الحالية تمت على مجموعتين من فران السمنة والبول السكري بالتغذية على بسكويات من الشوفان وقشور السوداني في مقابل البسكويات التجاري مع تقدير وزن الجسم المكتسب ومأخوذ الغذاء وجلوكوز الدم. وتم ذبح الحيوانات بعد ١٢ أسبوع من تلك المعاملة وعمل فحص وقطاعات بأنسجة الكبد والقلب والبنكرياس مع قياس كلا من كولسترول الدم والجليسريدات الثلاثية والكولسترول عالي الكثافة (HDL) والكولسترول منخفض الكثافة (LDL). وأوضحت النتائج أن الشوفان وقشور السوداني المستخدم لصناعة البسكويات لها تأثير على الخواص الحسية مع خفض وزن جسم الفران بالإضافة إلى مزايا علاجية. وأظهرت القياسات في سيرم الدم خفض الكولسترول الكلي وLDL والجليسريدات الثلاثية بينما ارتفع HDL وتحسنت الخواص الوظيفية بناء على فحص قطاعات الكبد والقلب والبنكرياس. وعلى ذلك باستهلاك أغذية من الشوفان وقشور السوداني يوميا له مزايا علاجية لمرضى السمنة والبول السكري.

الحلقات الكاشفة : ألياف غذائية - السمنة - البول السكري - البسكويات .