



Hypolipidemic Effect of Stirred Yoghurt Containing Potato Peels Extract on Rats

Hanan .S. Shalaby

Food Science Department, (Rural Home Economics) Faculty of Agriculture,
Zagazig University, Egypt

Abstract : In the present study, the effect of stirred yoghurt containing potato peels extract on hypolipidemic and tissues in rats were evaluated. Ethanolic extracts were prepared from the dried potato peels and their antioxidant activities, total phenolic content (TPC) and radical scavenging activity (RSA%), were determined. Results showed that the extract of PPE high antioxidant activities. Stirred yoghurt was prepared from low fat buffalos milk (3% fat) blended with 1 and 2% of PPE, before inoculation with the traditional yoghurt starter. Addition of PPE had no significant effects on the sensory attributes (appearance, body and texture and flavor) as compared to the control samples. Increasing the percentage of the added PPE resulted in decrease in the viscosity of the stirred yoghurt. Yoghurt containing blended of PPE. The scientific basis for blended of PPE use in biologically was examined. The results showed that PPE blended yoghurt were found to decrease the serum cholesterol, triglyceride and LDL-c but increase the HDL-c level as compared to hypercholesterolemic group. The histopathological examination of liver, heart and kidney exhibited more or less normalized in the groups fed with PPE blended yoghurt compared to the positive control group. Thus, the study demonstrates that PPE possesses a hypolipidemic effect in rats.

Key words: Antioxidant activities, total phenolic, organoleptic properties, liver and kidney functions.

Introduction

Yogurt is formed during fermentation of lactose from milk by lactic acid bacteria, and is one of the most popular fermented milks and traditionally consumed in many countries (Nakasaki *et al.*, 2008 and Shoriet *al.*, 2011). It is widely consumed as functional food because of

the good taste and nutritional properties (rich in potassium, calcium, protein and vitamins), being an important vehicle to provide probiotics to consumers (**Amirdivani et al., 2011**). There are increasing interests in applying fruit processing wastes as functional food ingredients since they are rich source of dietary fiber, and most of the beneficial bioactive compounds are remained in those by-products (**Balasundram et al., 2006**). Additionally, waste products (e.g. fruits and vegetables peels) from processing of agricultural commodities could offer practical and economic sources of natural antioxidants which could replace the synthetic ones (**Moure et al., 2001; Balasundram et al., 2006 and Reddy et al., 2007**).

Potatoes provide a natural source of phytochemicals such as carotenoids, phenolic compounds, flavonoids, and anthocyanins (**Akyol et al., 2016**) that help reduce the risk of chronic diseases, including cancer, age related neuronal degeneration, or cardiovascular diseases (**Habeebullah et al., 2012**). The health-promoting effects of potatoes are also very promising for humans study showed that the consumption of unpeeled cooked potatoes improves the lipid metabolism and antioxidant status in cholesterol fed rats (**Robert et al., 2006**). Phenolic acids, mainly chlorogenic acids, can consist of up to 90% of the total polyphenol content in potatoes (**Andre et al., 2007**). Phenolic compounds are mostly distributed between the potato cortex and skin (peel) tissues (**Arunet al., 2015**). About 50% of the phenolic compounds are located in the potato peel and adjoining tissues, while the rest decrease in concentration from the outside toward the center of potato tubers (**Al-WeshahyandRao, 2012**).

In a trid to open new ovenale for the using of potato peels with therapeutic nutrition, ethanolic extracts from potato peels were prepared and blended to yoghurt for improving its functional properties. Also, the effect feeding of such yoghurt on the blood lipid profiles hypercholesterolemic rats will being the scope of this investigation.

Materials And Methods

Materials:

Fresh low fat buffalo's milk (3% fat) was obtained from Dairy Technology Unit, Food Science Department, Faculty Agriculture, Zagazig University. Potato was obtained from the local market of Zagazig city. 1, 1 diphenyl-2-picrylhydrazyl radical (DPPH), ammonium

persulphate, rutin and Gallic acid from Sigma–Aldrich Inc. (St. Louis, MO,). Folin– Ciocalteus phenol reagents were purchased from Fluka Chemical Co. All the others solvent of buffers were purchased from Sd Fine-Chem. Limited .El-Gomhuria, company, Zagazig.

Starter Cultures:

Yoghurt culture containing of *Streptococcus salivarius* subsp. *thermophilus* EMCC104 and *Lactobacillus delbruekii* subsp. *bulgaricus* EMCC1102 were obtained from the Microbiological Resources Center (MIRCEN), Faculty of Agriculture , Ain Shams University, Egypt.

Methods

Preparation of potato peel powder

Potato fruits were washed by water and peeled carefully by Carborandum. Whole peels were air dried in a ventilated oven at 40°C for 48 h and ground to a fine powder.

Preparations of potato peels extract (PPE) Powder

Potato peel extract (PPE) was prepared according to **Shiban *et al.*, (2012), as follow:** 10 g of potato peels were separately blended for 2 min with 600 ml of 80% ethanol. The mixture was then left, in the dark; at room temperatures for 1 h prior to filtration (Whatman No. 1) and centrifuged at 3500 rpm for 10 min. Extracts were kept at - 20°C until analysis.

Determination of total phenolic compounds (TPC)

The concentration of TPC in the extract was measured UV spectrophotometer (Jenway-UV–VIS Spectrophotometer), based on a colorimetric oxidation/reduction reaction, as described by **Skerget *et al.*, (2005)** using Folin– Ciocalteu reagent. Specifically, 0.5 mL of diluted extract (10 mg in 10 mL solvent) was mixed with 2.5 mL of Folin– Ciocalteu reagent (diluted 10 times with distilled water) and 2 mL of Na₂CO₃ (75 g/1 L). The samples were incubated for 5 min at 50 °C then cooled. For a control sample, 0.5 mL of distilled water was used. The absorbance was measured at 760 nm. Total phenolic content expressed as Gallic acid equivalent (GAE) was calculated, and the results were expressed as an mg GAE/g extract.

Radical scavenging activity (RSA) of extracts

The electron donation ability of the obtained extracts was measured by bleaching of the purple colored solution of DPPH according to the method of **Hanato *et al.* (1988)**. One hundred of extract

(10 mg extract/10 mL solvent) was added to 3 mL of 0.1 mM DPPH dissolved in ethanol. The absorbance was determined against a control at 517 nm (**Gulcinet *al.*, 2004**). Percentage of antioxidant activity of DPPH was calculated as follows DPPH scavenging effect (%) = $[(A_0 - A_1) / A_0] \times 100$ where, A_0 is the absorbance of the control reaction and A_1 is the absorbance in the extract. Samples were analyzed in triplicate.

Identification of phenolic compounds using HPLC

Phenolic acids of the PPE were identified according to the method described by **Mattilaet *al.* (2000)**. HPLC (Hewlett Packard series 1050, USA) equipped with auto sampling, injector, solvent degasser, UV detector set at 330 nm and quarter HP pump (series 1050) was used. Column (C18 hypersil BDS) with particle size 5 μ m was used. The separation was carried out with methanol and acetonitrile as a mobile phase at flow rate of 1 mL/min. The column temperature was performed at room temperature (25°C) throughout the experiment. Identification and quantification were carried out based on calibrations of the standards prepared from phenolic acids dissolved in a mobile phase. Retention time and peak area were used for calculation of phenolic acid compounds by the data analysis of Hewlett Packard Software.

Stirred Yoghurt Manufacture

Fresh standardized milk (3% fat) was heated at 90 °C for 5 min and cooled to (40°C). The PPE was added at the ratios of 1%, and 2%, then 3% traditional starter culture was added and the mixtures were incubated at 45°C until the gel structure was formed. The gel was stirred after and stored at refrigerator (6 ± 2 °C) for 8 h.

Methods of analysis

Resultant yoghurt from all treatments was chemically analyzed for total solids and fat as described by **AOAC (2007)**. Total nitrogen percent were determined by semi-micro Kjeldhel method as described in the **AOAC (2007)**.

Rheological measurements

Viscosity: Viscosity of stirred yoghurt samples were determined by the method of **Aryana (2003)** using Rotational Viscometer Type Lab. Line Model 5437. Results were expressed as Cant Poise (CPS) .

Sensory evaluation:

Ten trained panelists from the staff members of Food Science Department, Faculty Agriculture, Zagazig University, Egypt used a quality rating score card for the evaluation of flavour (50 points) body and texture (40 points) and appearance (10 points).

Preparation of standard and high-cholesterol diets

-**Standard diet** (control diet) : the basal pellet diets obtained from the central animal house of the National Research Center ,Dokki, Giza, Egypt. This standard diet consisted of 20 % protein (casein), 5% fiber (cellulose),10% sucrose, 4.7%corn oil, 0.2% choline chloride, 0.3% methionin, 1% vitamin mixtures, 3.5% salt mixture. The remainder was corn starch. Salt and vitamin mixtures were prepared according to **Hegstedet. al.,(1941) and Campbell, (1963)**.

- **High-cholesterol diet:** the basal pellet diets which described above was grinded and supplemented with; 0.50% buffalo fat, 1% cholesterol and 0.25% biles acid.

Experimental design

Thirty healthy adult male albino rats weighing (130 -140 g) were divided into five groups, six rats per each. After the adaptation period (7 days), one group continued feeding on the basal diet and served as negative control (G1). Other groups were fed on high cholesterol diet for two weeks and were classified into sub groups as follow: Group (2) was fed on high cholesterol diet and served as a positive control (G 2). The third group was fed on 10% yoghurt without any additives (G 3). The fourth group was fed on10 % yoghurt blended with 1% PPE (G 4) and the fifth group was fed on 10% yoghurt blended with 2% PPE(G 5).All groups were feeding for6 weeks.

Biochemical analyses of lipids

Blood samples were collected using 5ml syringe by cardiac puncture. It was centrifuged at 3000 rpm for 10 min to separate serum. Cholesterol, HDL-c and triglyceride levels were estimated from serum methods described by **Devi and Sharma, (2004)**.LDL -cholesterol was calculated following the method by **Johnson et al. (1997)**. Liver enzymes, alanine amino transferase (ALT), aspartate amino transferase(AST) and total protein were determined using methods described by **Young(2001)**. Kidney functions were determined in serum creatinine and blood urea was determined as reported **Young (2001)**.

Histopathological examination

Specimens from liver, kidney and pancreas from all groups were examined then fixed in 10% neutral formalin and embedded in paraffin. Sections of five microns thickness were prepared, stained by haematoxylin and eosin as mentioned by **Suvarnaet.al., (2013)** and were examined microscopically.

Results And Discussion

Total phenolic compounds (TPC) and Radical scavenging activity (RSA) of PPE.

The results of TPC and RSA assays are presented in (Table 1).The data showed that PPE had a level of total phenols of 294.82 mg/100g. These results agree with that reported by **kong et al., (2012)**. Therefore, potato peel is a good source of bioactive compounds which have high antioxidative properties. The radical scavenging activity of the PPE showed 92.46%, Flavonoids and tannins that found in the plant are phenolic compounds that act as primary antioxidants or free radical scavengers (**Mohdaly et al., 2010 and Akyolet al.. 2016**).

Table (1).TPC and RSA of PPE

Parameter	PPE
TPC(mg/100g)	294.82
RSA(%)	92.46%

Identification of phenolic compounds by HPLC:

Table (2) shows the concentration of each phenolic compound in PPE there was a great variation among the identified components. It is suggested that there antioxidant activity is related to their cingulated rings and hydroxyl groups (**Mattilaet al., 2000**). Phenolic compounds identified in PPE ranged from 6.40 to 112.24 mg/100g. Phenolic compounds were identified in potato peels extract namely Vanillic acid, protocatechuic, Coumaric acid, caffien, catechin, and Eryptochlorogenic acid. The obtained results are similar to those reported by **Arun et al ., (2015) and konget al., (2012)**.

Table (2). Identification of phenolic compounds in ethanol extracts of potato peels as determined by HPLC

Test items	PPE (mg/100g)
Gallic	ND
Syringicacid	ND
Protocatechuic	7.82
Chlorogenic	22.68
Caffien	14.80
Catechin	8.42
Ferulic	ND
Cinnamic	ND
Quercetin	ND
Apigenin	6.40
Coumaric acid	18.36
Vanillic acid	112.24
Erythrochlorogenic acid	46.28

ND= Not detected

Chemical composition of stirred yoghurt

Data in Table (3) shows that stirred yoghurt made from milk containing 3% fat had the lowest total solids (TS) and it was different from all yoghurt treatments, while yoghurt blended with 2% potato peel extract (T2) exhibited the highest (TS) content, followed by yoghurt blended with 1% potato peel extracts (T1) . The TS content of yoghurt containing natural additives increased by increasing the percentage added. Also, Table (3) showed that, the control yoghurt (C) had slight increase in the fat content compared with other treatments. On the other hand, addition of natural extracts to milk did not affect the fat content of the resultant yoghurt. Furthermore, data shows that the yoghurt containing PPE had slight increase in the total protein (T1 and T2) compared with control yoghurt (C). The total protein of yoghurt with PPE slightly increased by increasing the percentage added. These results agree with that reported by **Yousef *et al.*, (2013)**.

Table (3): Chemical analysis of stirred yoghurt as affected by adding PPE

Samples	Total solids (%)	Total fat (%)	Total protein (%)
C	12.24±0.30 ^b	3.46±0.24 ^a	3.48±0.46 ^b
T1	12.52±0.32 ^{ab}	3.28 ±0.28 ^{ab}	3.62±0.42 ^{ab}
T2	12.98±0.35 ^a	3.22±0.26 ^b	3.84±0.43 ^a
LSD	0.2739	0.0210	0.319

Values with different letters in the same column are significantly different (P≤ 0.05)

C: control yoghurt T₁: yoghurt blended with 1% potato peels extract.

T₂: yoghurt blended with 2%.Potato peels extract

Rheological properties:

Viscosity of stirred yoghurt containing potato peel extract is shown in Table (4). Yoghurt samples containing PPE were significantly less viscous than control yoghurt. The decrease was proportional to the level of additives. This may be due to the addition of plant extracts generally decreased the viscosity of the products owing to reduced water-binding capacity of proteins. These results agree with that reported by **El-Said et al, . (2014)**.

Table (4): Viscosity of stirred yoghurt containing PPE

samples	Viscosity (CPS)
C	5700±14 ^a
T1	5260±18 ^b
T2	5180±13 ^c
LSD	3.408

Values with different letters in the same column or row are significantly different (P≤ 0.05)

Organoleptic Properties:

The average, score points given for appearance, flavour and body characteristics of yoghurt treatments containing PPE are illustrated in Table (5). Yoghurt containing PPE recorded the highest scores in sensory evaluation, and yoghurt containing PPE at the ratio of 2% (T2) showed better flavour intensity and body characteristics than the other yoghurt treatments. All yoghurt treatments were accepted by panelists. The blending improved yoghurt properties and over all acceptability. These results agree with that reported by **Gad et al., (2015)**.

Table (5): Organoleptic properties of yoghurt as affected by blended PPE

Samples	Appearance (10)	Flavour (50)	Body and texture (40)	Total (100)
C	8 ^a	46 ^b	37 ^a	91 ^c
T1	9 ^a	48 ^{ab}	37 ^a	94 ^b
T2	9 ^a	49 ^a	38 ^a	96 ^a
LSD	n.s	0.0210	0.7458	0.3388

Values with different letters in the same column are significantly different ($P \leq 0.05$)

Effect of yoghurt blending with PPE on blood lipid profile of hypercholesterolemic rats.

Feeding the rats with yoghurt blending PPE (10%) prevented the rise of mean serum TG, TC, and LDL-c concentrations after 3 and 6 weeks compare to hypercholesterolemic fed on basal diet rats (G2) with significant ($p \leq 0.05$) differences (Table 6). The HDL-c was increased by 10% in yoghurt blended with fed on 1% and 2% potato peel extract of rats (G4, G5) 56.615, 57.31, 60.74, 61.09 (mg/dl) respectively in 3, and 6 weeks and compare to hypercholesterolemic fed on basal diet rats (G2) 45.87, 3 weeks and 41.73 (mg/dl) 6 weeks where fed on 10% yoghurt blended with 2% PPE of rats was high values of (HDL-c) and the lowest in T.G and T.C values. Also LDL-c the low values was (G5) then (G4) in 3, and 6 weeks. Treatment with yoghurt blended PPE, significantly ($p \leq 0.05$) decreased the levels of total cholesterol and LDL-c as compare to the controls. This may be due to PPE containing antioxidants that could prevent and lower the free radicals level and lower liver LDL-c cholesterol uptake and protection of cortical neurons from cell death (Arunet *et al.*, 2015). These results agree with that reported by Kirazet *et al.*, (2010) and Mahmoud *et al.*, (2013) .

Table (6) :Effect of yoghurt blending with PPE on blood lipid profile of hypercholesterolemic rats.

Feeding period (weeks)	Groups	Triglycerides (mg/dl)	Total cholesterol (mg/dl)	HDL-c (mg/dl)	LDL-c (mg/dl)
2	-Ve	136.23±1.83 ^c	141.40±3.84 ^c	52.985±0.38 ^b	61.175±2.28 ^a
	+Ve	153.02±11.13 ^a	146.44±6.20 ^a	50.645±1.19 ^b	65.20±4.36 ^a
3	G1	143.51±4.68 ^c	119.12±8.61 ^{ef}	59.205±6.63 ^a	31.21±1.10 ^{cd}
	G2	167.30±9.24 ^d	152.06±2.35 ^b	45.875±0.79 ^a	72.73±0.28 ^b
	G3	151.35±3.76 ^b	128.353.71 ^d	50.050±5.03 ^b	48.03±2.19 ^c
	G4	154.49±4.39 ^a	122.11±1.43 ^e	56.615±2.70 ^{ab}	36.012±2.02 ^{cd}
	G5	149.35±7.31 ^b	114.71±3.06 ^f	57.310±0.24 ^{ab}	27.53±1.36 ^d
LSD		8.0757	6.0066	7.8698	5.9535
6	G1	149.92±3.41 ^c	126.24±3.34 ^c	60.770±1.01 ^a	35.485±1.64 ^e
	G2	175.78±1.65 ^b	157.64±0.83 ^b	41.730±0.14 ^c	80.76±0.26 ^c
	G3	160.13±3.69 ^b	129.89±0.16 ^c	50.815±0.53 ^{bc}	47.060±1.10 ^d
	G4	150.22±0.67 ^c	110.59±0.97 ^d	60.740±4.29 ^a	19.810±0.07 ^f
	G5	137.00±1.47 ^c	102.46±1.68 ^e	61.090±0.86 ^c	13.97±0.53 ^f
LSD		9.8684	5.2315	3.7065	4.3837

Values with different letters in the same column are significantly different ($P \leq 0.05$)

-Ve: Negative control group, normal rats fed on basal diet period

+Ve: Positive control group hypocholesterolemic rats and fed on basal diet period

G1 : Normal rats (negative control group) fed on basal diet all experiment period

G2 :Hypocholesterolemic rats fed on basal diet (Positive control group)

G3:Hypocholesterolemic rats fed on 10% yoghurt without any additives.

G4: Hypocholesterolemic rats fed on 10 % stirred yoghurt blended with 1% PPE

G5: Hypocholesterolemic rats fed on 10% stirred yoghurt blended with 2% PPE

Table (7) :Effect of yoghurt blending with PPE on liver functions of hypercholesterolemic rats.

Feeding period (weeks)	Groups	Total protein(g/dl)	ALT(U/L)	AST(U/L)
2	-Ve	6.6300±0.18 ^c	57.500±0.70 ^b	58.500±1.70 ^d
	+Ve	8.3850±0.20 ^a	72.500±0.71 ^a	75.500±0.70 ^b
3	G1	7.4450±0.30 ^b	67.000±1.41 ^b	65.500±2.12 ^c
	G2	7.3200±0.24 ^{bc}	77.500±2.12 ^a	87.500±2.32 ^a
	G3	7.3700±0.62 ^b	72.500±0.70 ^a	89.000±1.00 ^a
	G4	7.2850±0.88 ^c	67.000±1.41 ^a	75.500±0.70 ^b
	G5	7.4900±0.70 ^b	67.000±2.82 ^a	76.000±1.41 ^b
LSD		0.6922	1.9979	1.9619
6	G1	6.8200±0.11 ^c	67.500±0.70 ^a	75.500±0.70 ^b
	G2	7.6900±0.28 ^{ab}	77.500±2.12 ^a	87.500±2.12 ^a
	G3	6.9750±0.79 ^{bc}	72.000±1.41 ^a	88.000±1.41 ^a
	G4	6.9500±0.77 ^c	57.500±1.41 ^b	75.000±1.41 ^b
	G5	6.7350±0.86 ^c	57.000±0.72 ^b	74.000±2.82 ^b
LSD		0.8218	1.3613	1.9979

Values with different letters in the same column are significantly different (P≤ 0.05)

Effect of yoghurt blending with PPE on liver functions of hypercholesterolemic rats.

Table (7) shows that feeding rats on stirred yoghurt containing PPE (10%) prevented the rise of mean ALT, and AST activities. The rate of decreasing in the liver enzymatic activities were recorded 57.50, 57.00,

for ALT and 75.00, 74.00(U/L) for AST with the rat fed 10% of PPE 1% and 2% respectively. Also serum total protein were 6.950, (g/dl) and 6.735(g/dl) after 6 weeks with the rat fed 10% PPE1% and 2% respectively. These increasing levels were due to the liver cell injuries induced by high fat diet. Blending with PPE significantly ($p \leq 0.05$) decreasing in serum total protein, ALT, and AST levels. The obtained results are similar to those reported by **Loghai *et al.*, (2014)**. PPE was enriched with antioxidants that could prevent and lower the free radicals level. It had shown that the beneficial effects of this phytochemicals in preventing the ethanol-induced hepatotoxicity are mediated by the antioxidant effects. (**Arun *et al.*, 2015**).

Effect of yoghurt blending with PPE on Kidney functions of hypercholesterolemic rats.

Feeding of the rats with 10% stirred yoghurt containing PPE prevented the rise of mean serum creatinine and urea concentrations. The rate of prevention was increased with the increasing the extract concentrations (Table 8). The decreasing rate in the kidney function parameters were recorded 1.22 and 1.145(mg/dl) for creatinine and 41.42 and 40.58mg/dl for urea of 6 weeks with the rat fed on 10% stirred yoghurt 1% and 2% PPE, respectively. stirred yoghurt containing PPE showed antioxidant properties (**konget *al.*, 2012**). Dietary potato peel intake and potato peel components have demonstrated chronic disease, particularly for protection against cardiovascular disease and certain cancers (**Akyolet *al.*, 2016**). Emerging evidence supports additive and/or synergistic effects of potato peel components for protection against certain cancers (**Akyol *et al.*, 2016**). The obtained results are in agreement to those reported by (**Hassan *et al.*, (2011)** and **Ghalehkiet *al.*, (2012)**).

Table (8) :Effect of yoghurt blending with PPE on Kidney functions of hypercholesterolemic rats.

Feeding period (weeks)	Groups	Creatinine(mg/dl)	Urea(mg/dl)
2	-Ve	0.7350±0.07 ^e	38.340±0.42 ^f
	+Ve	0.9700±0.02 ^c	42.465±0.30 ^d
3	G1	0.8500±0.056 ^d	39.250±0.35 ^e
	G2	0.9300±0.04 ^c	44.735±0.33 ^{bc}
	G3	1.0300±0.056 ^b	44.500±0.35 ^c
	G4	0.9350±0.02 ^c	43.240±0.19 ^{ab}
	G5	1.0850±0.07 ^a	41.515±0.27 ^a
LSD		0.0518	0.6410
6	G1	0.7550±0.02 ^b	43.065±0.79 ^c
	G2	1.1800±0.05 ^{ab}	45.585±0.62 ^b
	G3	1.4850±0.68 ^a	45.390±0.55 ^a
	G4	1.2200±0.02 ^{ab}	41.425±0.10 ^a
	G5	1.1450±0.02 ^{ab}	40.585±0.68 ^a
LSD		0.6286	0.7398

Values with different letters in the same column are significantly different ($P \leq 0.05$)

Histological examination

Histological examination of the rats liver, heart, and kidney tissue as shown for 5 groups in Photo. (1-15).

Group G1, it was observed that liver had normal hepatic cord and kuffer cells were seen (Photo 1). Normal hepatic cord and swelling of muscle spaces or perivascular spaces conge dray blood vessels in heart (Photo 2).Kidney tissue was normal and focal tubular necrosis and other contain hyaline and albumin casts were noticed(Photo 3).

Group G2, it was indicted that liver was the hepatic parenchyma showed acute cell swelling and a few of them still revealed apoptotic changes. The hepatic blood vessels and sinusoid were dilated and congested. Portal and interstitial lymphocytic aggregations could be seen. A few portal areas showed intense fibrosis, edema, congestion and proliferative bile duct tubes beside hyperplastic kuffer cells were seen (Photo 4). Myocardial necrosis, inter and intra muscular edema, partial hyalinization of some myocardial muscle fiber were encountered in heart (Photo 5). Kidney examination cleared that nephrotic changes mainly fatty change with pyknotic nuclei in the majority of renal tubules beside congested blood vessels and glomeruli and capillaries were noticed. A few tubules still revealed focal coagulative necrosis. Hyaline and cellular casts could be seen inside the lumen of some tubules. Renal arteriole had hyalinized vessels wall and endotheliosis and perivascular edema. Focal fibrosis in cortex could be seen (Photo 6).

Group G3, it was showed that liver was portal and interstitial lymphocytic aggregations and infiltrations could be seen and portal fibroses (Photo7). Mild swellings of muscle fibers together, congestion and necrosis in heart (Photo 8). Wall of renal blood vessels showed mild endotheliosis and perivascular edema and focal interstitial lymphocytic nephritis and degenerated changes in kidney (Photo 9).

Group G4, it was cleared that liver was interlobular fibrosis with hylanized hepatic arteriole and cell swelling of hepatic cells were seen (Photo 10). Some portal area showed a few lymphocytic aggregations and facular degeneration in heart where was mild changes. The majority of cardiac myocytes were normal (Photo 11)and congestion hylanized and degeneration were lowest compare to Photo 8. Kidney was a few renal tubules still exhibited mild nephrotic changes together with albuminous and hyaline casts (Photo 12).

Group G5, it was found that the majority of the hepatic parenchyma revealed normally histological structures. Single portal area has slightly moderate bile duct proliferation beside congestion of hepatic blood vessels in liver (Photo 13). Heart cleared in the majority of cardiac structures was normal (Photo 14). Kidney was simple degenerated changes were noticed in the renal cortex (Photo 15). Some tubules showed albumins and hyaline casts and no edema.

These may be due to a high concentration of cholesterol being able to cause degeneration of hepatocytes. Most of the alterations in the examined sections due to the hypocholesterolemic diet were corrected more or less in the groups of rats that were fed on 10% stirred yoghurt supplemented with PPE. Also, high fat and high cholesterol levels present a contributing factor to pathologies including fatty liver and atherosclerosis and oxidative stress is considered to play a role in these pathologies (**Dimitrova, et al., 2010**). The obtained results are agree with those reported by **Mahmoud et al.,(2013)**.

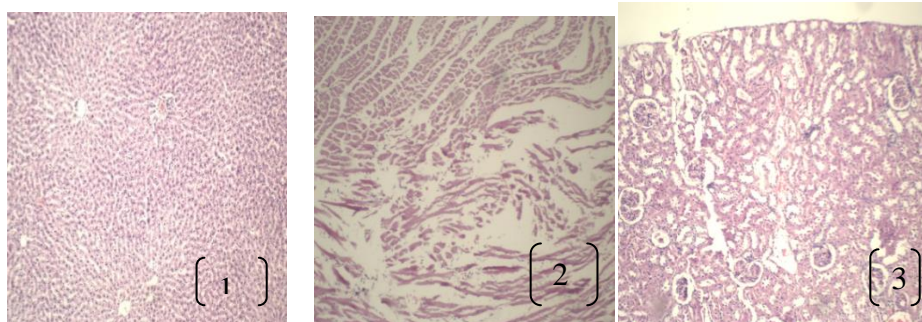


Photo 1: Liver tissue of normal (negative control) of ratG1 H&E (X300).

Photo2: Heart tissue of normal (negative control)of ratG1 H&E (X300).

Photo3: Kidney tissue of normal (negative control)of ratG1 H&E (X300).

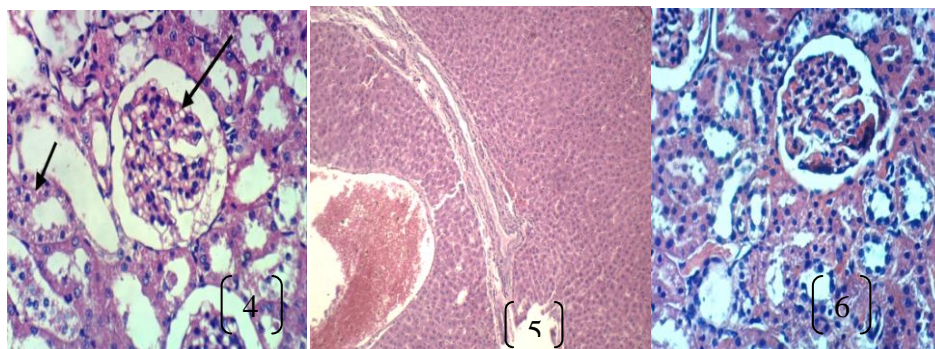


Photo4: Liver tissue of hypocholesterolemic rats (positive control of group G2) H&E (X1200).

Photo 5: Heart tissue of hypocholesterolemic rats (positive control of group G2) H&E (X300).

Photo 6: Kidney tissue of hypocholesterolemic rats (positive control of group G2) H&E (X1200).

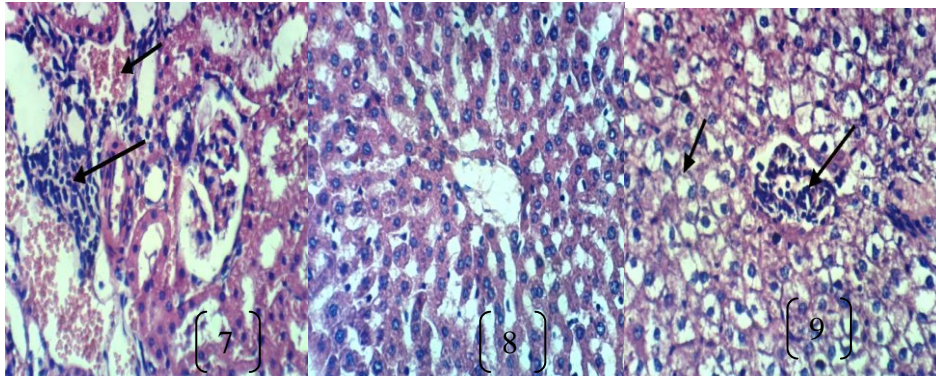


Photo7: Liver **tissue of** hypocholesterolemic rat and fed on 10% yoghurt without any additives G3 H&E (X300).

Photo8: Heart **tissue of** hypocholesterolemic rat and fed on 10% yoghurt without any additives G3 H&E (X300).

Photo 9: Kidney **tissue of** hypocholesterolemic rat and fed on 10% yoghurt without any additives G3 H&E (X300).

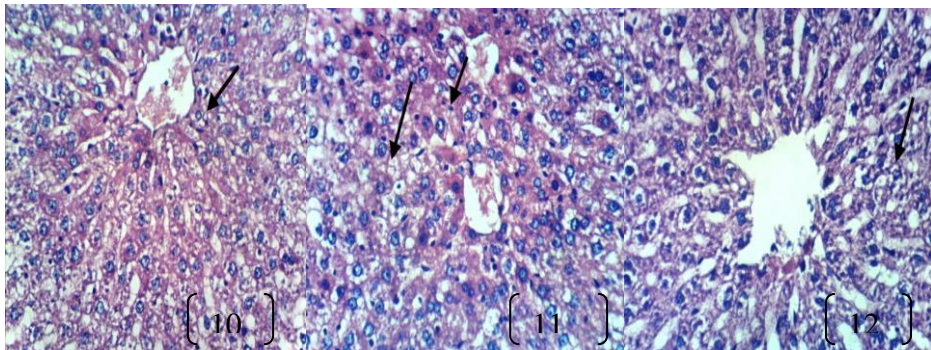


Photo10: Liver **tissue of** hypocholesterolemic rat and fed on 10% stirred yoghurt blended With 1% PPEG4H&E (X300).

Photo11: Heart **tissue of** hypocholesterolemic rat and fed on 10% stirred yoghurt blended with 1% PPEG4 H&E (X300).

Photo 12: Kidney **tissue of** hypocholesterolemic rat and fed on 10% stirred yoghurt blended with 1% PPEG4 H&E (X300).

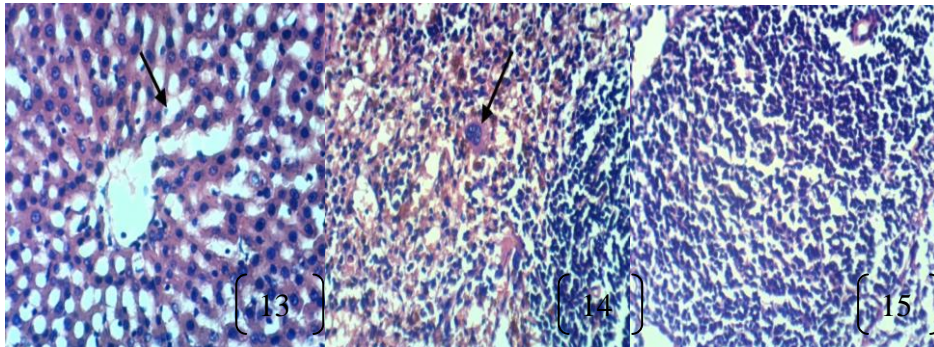


Photo13: Liver **tissue of** hypocholesterolemic rat and fed on 10% stirred yoghurt blended with 2% PPEG5 H&E(X300).

Photo14: Heart **tissue of** hypocholesterolemic rat and fed on 10% stirred yoghurt blended with 2% PPEG5 H&E (X1200).

Photo 15: Kidney **tissue of** hypocholesterolemic rat and fed on 10% stirred yoghurt blended with 2% PPEG5 H&E (X300).

Conclusion

Stirred yoghurt blending with PPE (1% and 2%) showed varying degrees of antioxidant activity. Therefore, it could be used as preservative ingredients in the food. PPE could be used as natural antioxidants in manufacture of yoghurt to improve its properties. Also, the observed cholesterol reducing effect of the PPE indicated the hypolipidemic activity. It can be recommended PPE as functional food and nutritional benefits to treat hypercholesterolemic or reduce the risk of atherosclerosis, improving liver and kidney functions.

□ □

References

- Akyol, H.; Ylenia, R.E.; Maria, C.; Fiorenza, C. and Verardo, V. (2016). Phenolic compounds in the Potato and its Byproducts: An Overview. *Int. J. Mol. Sci.* 17, 835.
- Amirdivani, S.; and Baba, A.S.(2011).Changes in yoghurt fermentation characteristics, and antioxidant potential and in vitro inhibition of angiotensin-1 converting enzyme upon the inclusion of peppermint, dill and basil. *Food Sci. Technol.* 44, 1458–1464.
- Andre, C.M.; Ghislain, M.; Bertin,P.; Oufir, M.; Herrera,M.D. and Hoffmann, L.(2007). Andean potato cultivars (*Solanumtuberosum L.*) as a source of antioxidant and mineral micronutrients. *J. of Agr. and Food Chem.* 55:366-378.
- AOAC.(2007). Association of Official Analytical Chemists – official method of analysis.(18th Ed.), Benjamin Franklin Station Washington, D.C.
- Arun, K.; Chandran, J.; Dhanya, R.; Krishna, P.; Jayamurthy, P.; and Nisha, P.(2015).A comparative evaluation of antioxidant and antidiabetic potential of peel from young and matured potato. *Food Biosci.* 9, 36–46.
- Aryana, K.J. (2003). Folic acid blended fat free plain set yoghurts. *Int. J. Dairy Technol.*, 56(4) : 219-222.
- Balasundran, N.; Sundram, K. and Samman, S.(2006). Phenolic compounds in plants and agri-industrial by-products: antioxidant activity, occurrence and potential uses. *Food Chem.* 99, 191–203.
- Campbell, J.A. (1963). Methodology of Protein Evaluation. RAG: Nutr., Document R.101 add. 37 June Meeting, New York.
- Devi, R.K. and Sharma, D.K. (2004).Hypolipidemic effect of different extracts of *ClerodendroncolebrookianumWalp* in normal and high-fat diet fed rats. *J. Ethnopharmacol.* 90:63-68.
- El-Said,M. M.; Haggag, H.F. ; Fakhr El-Din H. M.;Gad, A.S. and Farahat, M. (2014). Antioxidant activities and physical properties of stirred yoghurt blended with pomegranate peel extracts. *Ann. of Agr. Sci.*, 59(2):207–212.
- Gad, A.S.; Ebtisam I.; Ghita, H. M.F; Badran S.M. A. and Tamer, M. E.(2015). Evaluation yogurt blended with vegetable and fruit juice as natural sources of antioxidant. *Inter. J. of Food and Nutr. Sci.*, 4, (3) , 2320 –7876.
- Ghalehkandi. J.; Yahya, E. and Ramin, S. N. (2012).Effect of Garlic (*Allium sativum*) Aqueous Extract on serum values of urea, uric-

- acid and creatinine compared with chromium chloride in male rats. *Ann. of Bio. Res.*, 2012, 3 (9):4485-4490.
- Habeebullah, S.F.K.; Grejsen, H.D. and Jacobsen, C.(2012). Potato peel extract as a natural antioxidant in chilled storage of minced horse mackerel (*Trachurustrachurus*): Effect on lipid and protein oxidation. *Food Chem.*131:843–851.
- Hanato, T.; Kagawa, H.; Yasuhara, T. and Okuda, T.(1988). Two new flavonoids and other constituents in licorice root: Their relative astringency and radical scavenging effects. *Chem. Pharm. Bull.* 36, 2090–2097.
- Hassan.S. ;Abd El-Twab, S.; Hetta, M. and Mahmoud, B.(2011). Improvement of lipid profile and antioxidant of hypercholesterolemic albino rats by polysaccharides extracted from the green alga *Ulvalactuca Linnaeus*. *Saudi Journal of Biol. Sci.* 18: 333–340.
- Hegested, D. : Mill, R. and Perkins, E. (1941). Salt mixture. *J. Biol. Chem.*, 138:45g.
- Johnson, R. ; McNutt, P. ;MacMahon, S. and Robson, R.(1997). Use of the friedewald formula to estimate LDL-cholesterol in patients with chronic renal failure on dialysis. *Clin. Chem.* 43: 2183-2184.
- Kiraz Z. K.; Mehmetçik G.; Dogli S. and Uysal1M. (2010). Artichoke leaf extract reduces oxidative stress and lipoprotein dyshomeostasis in rats fed on high cholesterol diet. *Phytother. Res.* 24: 565–570 .
- Kong A.H. ; Carolina, F.; Susan, H. ; Andrés, C.; Antonio, V. G. and Roberto, L. M. (2012). Antioxidant capacity and total phenolic compounds of twelve selected potato landrace clones grown in southernchile. *Chilean J. of Agri. Res.* 72(1).
- Mahmoud, H.; Abdel-Hady, A. and Badawi, G.M. (2013). Hypocholesterolemic effect of antioxidant containing fruits in rats fed on high-cholesterol and fat diet. *J. of App. Sci. Res.*, 9(7): 4233-4244.
- Mattila, P.; Astola, J. and Kumpulainen, J. (2000). Determination of flavonoids in plant material by HPLC with diode-array and electroarray detections. *J. Agric. Food Chem.* 48, 5834–5841.
- Mohdaly, A.; Sarhan, M.; Mahmoud, A.; Ramadan, M. and Smetanska, I.(2010).Antioxidant efficacy of potato peels and sugar beet pulp extracts in vegetable oils protection. *Food Chem.*, 123, 1019–1026.
- Moure, A.; Cruz, J .M.; Francob, D.; Dominguez, J. M.; Sineirob, J.; Dominguez, H.; Nuinez, M.J. and Parajo J.C. (2001). Natural

- antioxidants from residual sources –A review. *Food Chem.* 72, 145–171.
- Nakasaki, K.; Yanagisawa, M. and Kobayashi, K.(2008).Microbiological quality of fermented milk produced by repeated-batch culture. *J. Biosci. Bioeng.* 105, 73–76.
- Reddy, M.; Gupta, S.; Jacob, M.; Khan, S.and Ferreira, D. (2007).Antioxidant, antimalarial and antimicrobial activities of tannin rich fractions, ellagi tannins and phenolic acids from *Punicagranatum*L.Planta Med. 73, 461–467.
- Robert, L.; Narcy A.; Rock, E.; Demigne, C.; MazurA. and Révész,C. (2006). Entire potato consumption improves lipid metabolism and antioxidant status in cholesterol-fed rat. *European J. of Nutr.* 45:267-274.
- Shiban, M.S.; Al Otaibi, M.M. and Al-Zoreky, N.S. (2012). Antioxidant activity of pomegranate (*Punicagranatum* L.) fruit peels. *Food Nutr. Sci.* 3, 991–996.
- Shori, A.B. and Baba, A.S.(2011). Comparative antioxidant activity, proteolysis and in vitro α -amylase and α -glucosidase inhibition of *Allium sativum*-yogurts made from cow and camel milk. *J. Saudi Chem. Soc.* doi:10.1016/j.jscs. 09.014
- Skerget, M.; Kotnik, P.; Hadolin, M.; Rizner, H. A.andSimonici K.M.(2005). Phenols, proanthocyanidins, flavones and flavonols in some plant materials and their antioxidant activities. *Food Chem.* 89, 191–198.
- Suvarna, S.K., Layton C. and Bancroft,J.D. (2013).Bancroft’s Theory and Practico of Histological Technigues.7th Ed., Churchill Livingstone. Elsevier, England.
- Young, D.S. (2001). Effects of disease on clinical lab tests, 4th ed. AACC. (www.hayah.cc/from/t34135.html).
- Yousef, M. ;Nateghi, L. and Azadi, E. (2013). Effect of different concentration of fruit additives on some physicochemical properties of yoghurt during storage. *Annals of Biol. Res.*, 2013, 4 (4):244-249.

التأثير الخافض لدهون الدم لليوغورت المقلب المحتوى على مستخلص قشور البطاطس في الفئران

حنان سعيد توفيق شلبي

(قسم علوم الأغذية (شعبة الاقتصاد المنزلي الريفي) كلية الزراعة- جامعة الزقازيق)

الملخص العربي

أجريت هذه الدراسة بغرض إعداد مستخلص كحولي من قشور البطاطس. تم تقدير النشاط المضاد للأكسدة للمستخلص من حيث محتوى المواد الفينولية ومنع تكوين الشقوق الحرة وتفريد المواد الفينولية بجهاز الفصل الكروموتوجرافي . وأوضحت النتائج احتواء المستخلص الكحولي لقشور البطاطس على نسبة من المواد الفينولية الكلية (٢٩٤,٨٢ ملجم / ١٠٠ جم) ونشاطه القوي المضاد للأكسدة (٩٢,٤٦ %) . تم إضافة المستخلص الكحولي لقشور البطاطس باليوغورت المقلب بنسب ١,٢ % . وأوضحت النتائج أن إضافة مستخلص قشور البطاطس إلى اليوغورت المقلب لمتأثر بشكل ملحوظ على التركيب الكيماوي وأوضحت خواص حسية جيدة ولكنها قلت من لزوجة المنتج مقارنة بالعينات الضابطة . كذلك تم استخدام اليوغورت المقلب المحتوى على نسب ١,٢ % من مستخلص قشور البطاطس في تغذية الفئران . وأظهرت النتائج أن الفئران (ذات المحتوى العالي لكوليستيرول الدم) التي تم تغذيتها على اليوغورت المقلب والمضاف إليه مستخلص قشور البطاطس قد أدت إلى انخفاض في محتوى كوليستيرول الدم والدهون الثلاثية والليبوبروتين منخفض الكثافة بينما زاد محتوى الليبوبروتين عالي الكثافة و اضاقتة أدت إلى حدوث تحسن في وظائف الكبد والقلب والكلية. وبإجراء فحص هستولوجي لأنسجة القلب والكبد والكلية للفئران محل الدراسة حدث تحسن وعلاجات في قطاعات الكبد والقلب والكلية لمجموعة الفئران التي تم تغذيتها على اليوغورت المقلب المدعم بمستخلص قشور البطاطس مقارنة بالمجموعة الضابطة . ومن خلال هذه النتائج يتضح أن اليوغورت المقلب المحتوى على مستخلص قشور البطاطس بنسب ١,٢ % لدية تأثير خافض للدهون الضار ب الدم لذلك يمكن التوصية بإضافته أثناء صناعة اليوغورت المقلب للحصول على الفوائد الصحية والغذائية لهذا المنتج.

الكلمات المفتاحية : النشاط المضاد للأكسدة -الفينولات الكلية - الخواص الحسية . وظائف الكبد والكلية .